



## The role of three-phase $^{99m}\text{Tc}$ -MDP bone scintigraphy in the diagnosis of periprosthetic joint infection of the hip and knee

Uloga trofazne scintigrafije kostiju sa  $^{99m}\text{Tc}$ -MDP u dijagnozi periprotetske infekcije kuka i kolena

Dragan Pucar\*, Zoran Janković\*†, Zoran Baščarević‡, Srdjan Starčević†§,  
Milica Čizmić†||, Marija Radulović\*

Military Medical Academy, \*Institute of Nuclear Medicine, §Clinic for Orthopedic Surgery and Traumatology, ||Clinic for Endocrinology, Belgrade, Serbia; University of Defence, †Faculty of Medicine of the Military Medical Academy, Belgrade, Serbia; University of Belgrade, Faculty of Medicine, ‡Institute for Orthopedic Surgery “Banjica”, Belgrade, Serbia

### Abstract

**Background/Aim.** In the last five decades primary hip and knee arthroplasty is the most common and effective surgical intervention worldwide. Infection, although unfrequented, is the most serious complication. Nuclear medicine imaging, not affected by metallic hardware, is the current imaging modality of choice for the evaluation of suspected joint replacement infection. The aim of this study was to estimate the diagnostic accuracy of three phase  $^{99m}\text{Tc}$  methylene diphosphonate ( $^{99m}\text{Tc}$ -MDP) bone scintigraphy in periprosthetic hip and knee joint infection. **Methods.** Inclusion criteria of patients in the study were suspected knee or hip periprosthetic joint infections. In this study, we examined 45 patients (14 men and 31 women) with 39 hip and 24 knee prosthesis (total 63). In all patients, three-phase bone scintigraphy was performed after intravenous application of 555 MBq of  $^{99m}\text{Tc}$ -MDP. The final confirmation of infection was microbiological or pathohistology finding. **Results.** Infection was confirmed in 29 prosthetic joints, in 13 (44.8%) knee and 16 (55.2%) hip joints while there was no infection in 34 prosthetic joints. The connection of different modalities of negative and positive findings  $^{99m}\text{Tc}$ -MDP

three-phase bone scintigraphy with the final confirmation of infection showed a high statistical significance ( $p < 0.001$ ). Three phase bone scintigraphy showed a high sensitivity of 90% but a modest specificity of 69.7% in the detection of periprosthetic infection with the diagnostic accuracy of 79%. The calculated positive predictive value was 73% but the negative predictive value was high 89%. Our results of three-phase bone scintigraphy with calculated sensitivity, specificity and diagnostic accuracy of 79% are in consent with the majority of published studies, or even slightly better. **Conclusion.** Bone scintigraphy is sensitive in the diagnosis of periprosthetic infection but insufficiently specific. In the detection of periprosthetic infections three-phase bone scan can be used as a diagnostic method of the first line only aimed at its exclusion. The only reasonable use of bone scintigraphy is in combination with other radionuclide methods with high specificity.

**Key words:** hip prosthesis; knee prosthesis; infection; diagnosis; sensitivity and specificity; technetium  $^{99m}\text{Tc}$  medronate.

### Apstrakt

**Uvod/Cilj.** U poslednjih pet decenija primarna artroplastika kuka i kolena predstavlja jednu od najčešćih i najefikasnijih hirurških intervencija širom sveta. Infekcija, iako retka, jeste najozbiljnija komplikacija. Nuklearno medicinsko snimanje, koje nije ometeno metalnim hardverom protesnog zgloba, je trenutno modalitet izbora za procenu sumnje na periprotetsku infekciju zgloba. Cilj ovog istraživanja bio je da se proceni dijagnostička tačnost trofazne  $^{99m}\text{Tc}$  metylene diphosphonate ( $^{99m}\text{Tc}$ -MDP) scintigrafije kostiju kod

periprotetske infekcije kuka i kolena. **Metode.** Kriterijumi za uključivanje bolesnika u studiju bili su postojanje sumnje na periprotetsku infekciju zgloba kuka i kolena. U ovoj studiji smo ispitivali 45 bolesnika (14 muškaraca i 31 ženu) sa 39 implanta kuka i 24 proteze kolena (ukupno 63). Kod svih bolesnika bila je urađena trofazna scintigrafija skeleta nakon intravenske aplikacije 555 MBq  $^{99m}\text{Tc}$ -MDP. Konačna potvrda infekcije ustanovljena je bio mikrobiološkim ili patohistološkim nalazom. **Rezultati.** Infekcija je bila potvrđena kod 29 protetskih zglobova, 13 (44,8%) kolena i 16 (55,2%) kuka, a isključena kod 34 protetska zgloba. Povezanost raz-

ličitih modaliteta negativnih i pozitivnih nalaza  $^{99m}\text{Tc}$ -MDP trofazne scintigrafije kostiju sa konačnom potvrdom infekcije pokazuje visoku statističku značajnost ( $p < 0,001$ ). Trofazna scintigrafija skeleta pokazala je visoku osetljivost od 90%, ali skromnu specifičnost od 69,7% u otkrivanju periprotetske infekcije, dok je dijagnostička tačnost bila 79%. Izračunata pozitivna prediktivna vrednost za metodu iznosila je 73%, ali negativna prediktivna vrednost bila je visoka (89%). Naši rezultati trofazne scintigrafije skeleta sa vrednostima osetljivosti od 90%, specifičnosti od 69,7% i dijagnostičke tačnosti od 79% u saglasnosti su sa većinom objavljenih studija, pa i diskretno bolji. **Zaključak.** Scintigrafija ske-

leta je osetljiva metoda u dijagnostici periprotetske infekcije, ali je nedovoljno specifična. U otkrivanju periprotetske infekcije, trofazna scintigrafija kostiju može se koristiti kao dijagnostička metoda prve linije samo u cilju njenog isključivanja. Jedino razumno korišćenje scintigrafije kostiju je u kombinaciji sa drugim radionuklidnim metodama visoke specifičnosti.

#### Ključne reči:

**kuk, proteza; koleno, proteza; infekcija; dijagnoza; senzitivnost i specifičnost; tehnecijum  $^{99m}\text{Tc}$  medronat.**

## Introduction

Over the last five decades primary hip and knee arthroplasty procedures have been among the most common and effective surgical intervention worldwide<sup>1</sup>. The number of performed joint replacements has significantly increased in response to demographic change. The number of total hip arthroplasties (THA) carried out in the USA increased 2.5 times from 200,216 in 1993 to 497,419 in 2005. In the same period, the amount of primary total knee arthroplasties (TKA) grew 1.7-fold<sup>2</sup>. The most implanted artificial joints are hip and knee prostheses (more than 95%). Patients who failed conservative and comprehensive care may be considered for joint replacement surgery. Intractable pain, severe osteoarthritis (OA), and limitation of motion are the main reasons to consider joint replacement surgery. Inability to flex the knee more than 90 degrees considerably limits the functional capacity of rising from a chair. Life expectancy is also an important consideration regarding the longevity of joint replacements and the risk of future loosening or implant failure. However, some patients have prosthesis more than 20 years. The most important contraindications are an acute infection and severe obesity, while relative contraindications include: poor health and high anesthetic risks, poor bone stock, significant deformities, severe neuropathy. Although hip or knee joint replacement is highly successful surgical intervention, long-term outcomes continue to suffer from aseptic loosening and periprosthetic joint infection (PJI). More than 25% of all prostheses will demonstrate evidence of loosening, often after a revision arthroplasty<sup>3</sup>. Most authors agree that many cases understood as aseptic failure may be due to an unrecognized infection.

Infection, although unfrequented, is the most serious complication. In patients with primary joint replacement, the infection rate in the first 2 years usually ranges from 0.5 to 2%. Commonly isolated microorganisms are Gram-positive cocci: coagulase-negative *staphylococci*, *Staphylococcus aureus*, and *enterococci* (65%)<sup>4</sup>. Infection rates after a surgical revision are usually higher (25% to 40%) than after a primary replacement<sup>5</sup>. Important risk factors for arthroplasty are a postoperative surgical site infection, previous arthroplasty, older age, malnutrition, joint disease, obesity, diabetes mellitus, remote infection<sup>6,7</sup>.

Increased erythrocyte sedimentation rate (ESR) and high C-reactive protein (CRP) levels are sensitive for non-

specific inflammation but not specific for PJI. Findings such as radiolucency, osteolysis, and migration obtained by plain radiography are not enough sensitive or specific and may be present in both infection and aseptic loosening<sup>8</sup>. Cross-sectional imaging techniques, such as computed tomography and magnetic resonance imaging, are of limited value in the presence of metallic prosthetic implants owing to beam hardening and dephasing artefacts<sup>9</sup>.

Nuclear medicine imaging, which is, in general, not affected by metallic hardware, is the current imaging modality of choice for the evaluation of suspected joint replacement infection<sup>10</sup>. One of the oldest radionuclide imaging modalities used for this purpose is bone scintigraphy (BS)<sup>11</sup>. BS is widely available, relatively inexpensive, easily performed, and quickly completed. Uptake of bone-seeking tracer such as  $^{99m}\text{Tc}$  methylene diphosphonate ( $^{99m}\text{Tc}$ -MDP), which accumulates on the surface of the bone mineral matrix, depends on blood flow and especially on the rate of new bone formation<sup>12</sup>. The cause of accelerated new bone formation may be seen as increased periprosthetic activity on BS in infection, but also in the postoperative physiological bone remodeling, as well as pathological conditions such as fracture, heterotopic ossification and aseptic loosening. Persistent uptake more than 12 months after arthroplasty is usually abnormal. In general, BS is highly sensitive but not very specific for PJI. The literature on the diagnostic efficiency of bone scintigraphy shows a considerable variability due to several factors, such as the use of different scan interpretation criteria (quantitative vs qualitative approach) and performing a three-phase study instead of only a delayed bone scan.

The aim of this study was to estimate the diagnostic accuracy of three phase  $^{99m}\text{Tc}$ -MDP bone scintigraphy in periprosthetic hip and knee joint infection.

## Methods

A total of 45 patients (14 men and 31 women) with 39 implanted hip and 24 knee prosthesis (total 63) were included in this study. The mean age of patients was 68.6 (range 43–82) years. The study was performed during a 5-months period from August 2015 to January 2016. Criteria for including patients in this study were suspected PJI based on: painful prosthetic joint (especially in locomotion but also in peace), restricted joint movements and increased value of erythrocyte sedimentation rate and/or high levels of C-reactive protein. All patients underwent plain radiography.

In all patients, after intravenous injection of 555 MBq  $^{99m}\text{Tc}$ -MDP, three-phase bone scintigraphy was performed on ADAC vertex gamma camera using a large field of view dual detectors filtered with low energy all-purpose collimator. Imaging was performed at various times in supine position: 0–5 minute (15 frames in the first minute and 6 frames in further 4 minutes), 6–10 minute (one frame with 300 seconds duration) and late static imaging after 3 hours. Scintigrams were analyzed visually without any quantification.

The bone scintigraphy findings were semiquantitative: value 1 – normal, 2 – borderline normal, 3 – borderline abnormal, and 4 – clearly abnormal. The final diagnosis of infection was confirmed by microbiological or histopathological results.

For the purpose of an initial analysis and description, usual descriptive statistics were used (mean age, standard deviation, number and percentage of frequency characteristics within a given set). To test the statistical significance of differences the results of bone scintigraphy were compared with the

gold standard. The  $\chi^2$  test was used and statistically significant differences were evaluated at a level of at least  $p < 0.05$ .

A software package SPSS version 18.0 (USA) was used. Sensitivity, specificity and predictive values of bone scintigraphy were calculated using the standard formulas.

## Results

Descriptive parameters of patients are shown in Table 1.

The relationship between the results of three-phase  $^{99m}\text{Tc}$ -MDP bone scintigraphy and confirmed infection is shown in Table 2.

Infection was confirmed in 29 prosthetic joints – 13 (44.8%) knee and 16 (55.2%) hip joints, while not found in 34 patients.

The association between different modalities of negative and positive findings of  $^{99m}\text{Tc}$ -MDP three phase bone scintigraphy crossed with the final confirmation of infection showed high statistical significance ( $p < 0.001$ ).

**Table 1**

Descriptive parameters of the patients	
Parameters	Values
Age (years), mean $\pm$ SD	68.64 $\pm$ 9.56
Gender, n (%)	
male	14 (31.1)
female	31 (68.9)
Confirmation of infection (the gold standard), n (%)	
confirmed	16 (35.6)
unconfirmed	29 (64.4)
Total	45 (100.0)

SD – standard deviation

**Table 2**

### The relationship between the results of $^{99m}\text{Tc}$ -MDP and confirmed infection

Results of $^{99m}\text{Tc}$ -MDP scyntigraphy	Infection		Total
	No	Yes	
Negative finding			
n	9	0	9
MDP finding (%)	100.0	0.0	100.0
Infection (%)	26.5	0.0	14.3
Borderline negative finding			
n	14	3	17
MDP finding (%)	82.4	17.6	100.0
Infection (%)	41.2	10.3	27.0
Borderline positive finding			
n	5	6	11
MDP finding (%)	45.5	54.5	100.0
Infection (%)	14.7	20.7	17.5
Positive finding			
n	6	20	26
MDP finding (%)	23.1	76.9	100.0
Infection (%)	17.6	69.0	41.3
Total			
n	34	29	63
MDP finding (%)	54.0	46.0	100.0
Infection (%)	100.0	100.0	100.0
Significance	$\chi^2 = 23.498; p < 0.001$		

$^{99m}\text{Tc}$ -MDP – technetium methylene diphosphonate.

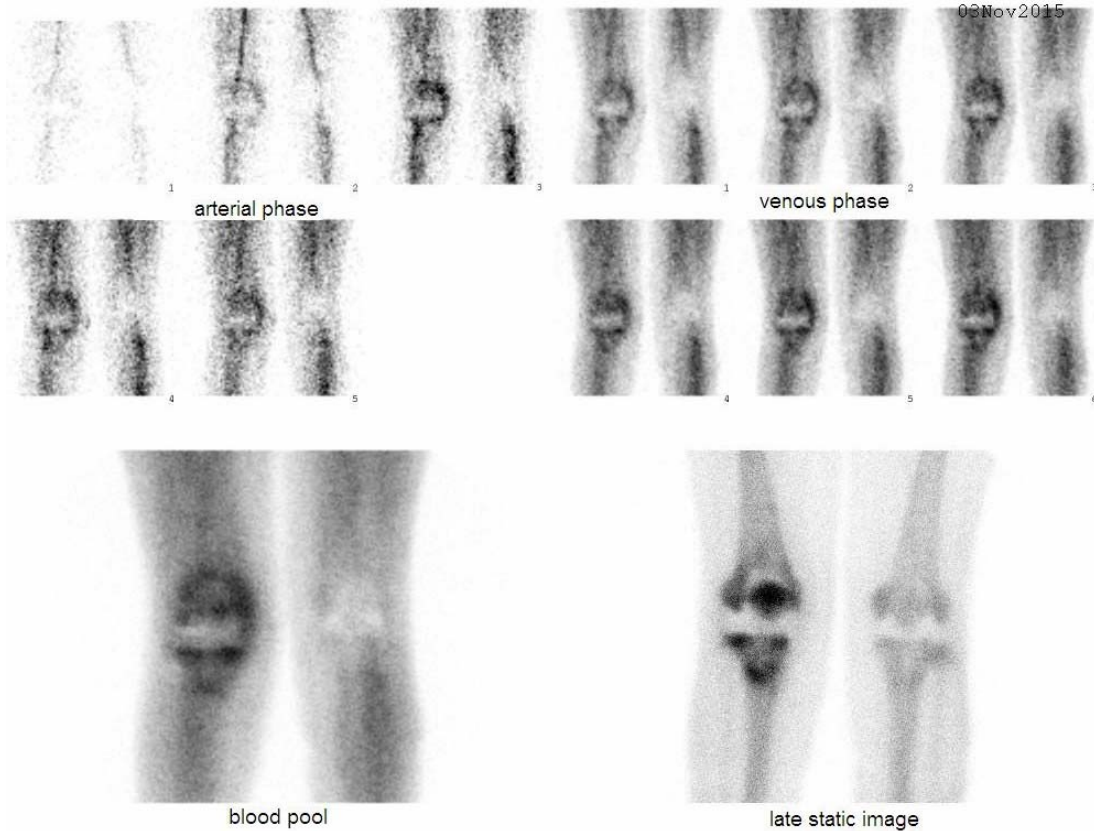
Three phase bone scintigraphy had a high sensitivity of 90% but a modest specificity of 69.7% in detecting periprosthetic joint infection, with a diagnostic accuracy of 79%. Calculated positive predictive value (PPV) was 73%, but the negative predictive value was high – 89%.

Clearly positive findings of <sup>99m</sup>Tc-MDP three-phase bo-

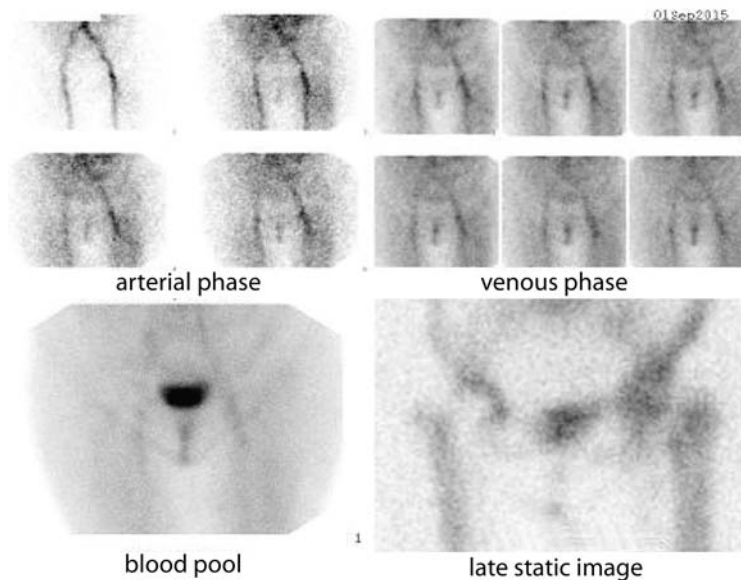
ne scintigraphy in detecting periprosthetic joint infection of the knee are shown in Figure 1.

The high negative predictive value of 89% resulted in a frequent number of true negative findings (Figure 2).

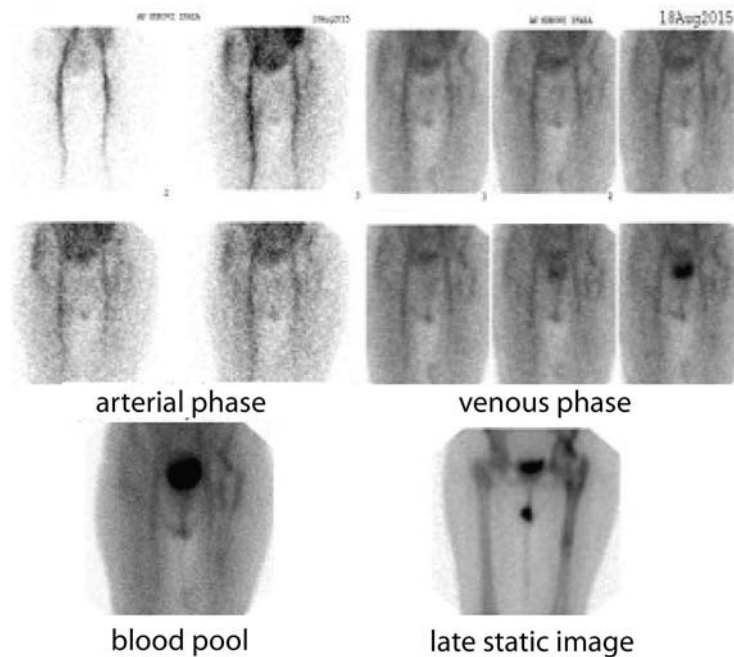
Modest specificity of 69.7% in detecting periprosthetic joint infection resulted in false positive findings (Figure 3).



**Fig. 1 – A 72-year-old female patient with bilateral knee joint replacement. In the region of right knee replacement extensive increased activity is observed in all three phase of bone scintigraphy indicating infection.**



**Fig. 2 –The results of three-phase <sup>99m</sup> technetium methylene diphosphonate (<sup>99m</sup>Tc-MDP) bone scintigraphy are negative at all stages of the imaging. Definite result: inadequate joint biomechanics due to adductor muscle weakness – aseptic.**



**Fig. 3 – Positive findings at all stages of the imaging (increased uptake in the region of the greater trochanter and discretely increased along the femoral stem). Definitive result: aseptic loosening.**

### Discussion

Assessment of the presence of periprosthetic joint infection using bone scan is considered problematic by many authors. Persistently increased binding of radiopharmaceuticals in the first year after application of arthroplasty, suggesting accelerated bone remodeling, occurs in approximately 60% of cases around the femoral component of the prosthesis and in about 90% around the tibial component<sup>13-15</sup>.

Most authors agree that the accuracy of bone scintigraphy in the evaluation of possible causes of painful prosthesis varies between 50 and 70% and that it is too low value for its clinical use unless combined with some other radionuclide imaging method of higher specificity<sup>16</sup>.

However, according to the recent study of Zajonz et al.<sup>2</sup>, which included 320 prosthetic hip and knee joints, the obtained accuracy of three-phase bone scintigraphy was as much as 90%. Probably the greatest advantage of using this method alone is its high negative predictive value of 95%, making it a screening method with a high probability of periprosthetic joint infection of the hip and knee<sup>17</sup>. In that case should not be forgotten that the negative predictive value is lower in the first year after arthroplasty and that two-thirds of infections occur precisely in that period<sup>8</sup>.

Early efforts made by some authors in differentiating aseptic loosening from periprosthetic joint infection by analyzing the increased uptake were very interesting. Williamson et al.<sup>18</sup> found in 1979 that the focal zone of increased radiopharmaceutical uptake indicated aseptic loosening, while diffused increased radiopharmaceutical binding around the femoral or acetabular endoprosthesis indicated infection. Two years later, Williams et al.<sup>19</sup> reported that diffusely increased radiopharmaceutical binding around the

implant might be an indication of infection and aseptic loosening. Aliabadi et al.<sup>20</sup> published in 1989 that bone scan could accurately detect loosening, but not separate aseptic loosening from the loosening caused by the presence of infections. Palestro et al.<sup>21</sup> have long argued that bone scintigraphy is neither enough sensitive nor specific method in the diagnosis of a periprosthetic knee infection. This statement was supported by some recent studies, except when it comes to its sensitivity. The accuracy of this method is slightly increased if carried out as a three-phase scintigraphy. In 2008 Love et al.<sup>16</sup>, considering 150 prosthetic lower limb joints (96 joints of the hip and 54 joints of the knee), obtained a sensitivity of 76% and specificity of 51% in the diagnosis of infection. Diagnostic accuracy of 50% was obtained if only delayed static scintigraphy was done and increased to 62% when performed as a three-phase bone scintigraphy.

Our results of three-phase bone scintigraphy (diagnostic sensitivity 90%, specificity 69.7% and accuracy 79%) are in consent with the majority of published studies and even slightly better.

### Conclusion

Bone scintigraphy is sensitive in the diagnosis of periprosthetic joint infection, but due to its unacceptable specificity, it is not a method that could work independently and can not be used alone for detecting a periprosthetic joint infection. For that purpose, the three-phase bone scan can be used as the first line diagnostic method just for the definitive exclusion of infection. The only realistic possibility to use bone scintigraphy to detect a periprosthetic joint infection is its combination with other radionuclide methods of high specificity.

## R E F E R E N C E S

1. Osmon DR, Berbari EF, Berendt AR, Lew D, Zimmerli W, Steckelberg JM, et al. Executive summary: Diagnosis and management of prosthetic joint infection: Clinical practice guidelines by the Infectious Diseases Society of America. *Clin Infect Dis* 2013; 56(1): 1–10.
2. Zajonz D, Wuthe L, Tiepolt S, Brandmeier P, Prietzel T, von Salis-Soglio GF, et al. Diagnostic work-up strategy for periprosthetic joint infections after total hip and knee arthroplasty: a 12-year experience on 320 consecutive cases. *Patient Saf Surg* 2015; 9: 20.
3. Kurtz S, Ong K, Lau E, Mowat F, Halpern M. Projections of primary and revision hip and knee arthroplasty in the United States from 2005 to 2030. *J Bone Joint Surg Am* 2007; 89(4): 780–5.
4. Lentino JR. Prosthetic joint infections: Bane of orthopedists, challenge for infectious disease specialists. *Clin Infect Dis* 2003; 36(9): 1157–61.
5. Zimmerli W, Trampuz A, Ochsner PE. Prosthetic-joint infections. *N Engl J Med* 2004; 351(16): 1645–54.
6. Kessler B, Sendi P, Graber P, Knupp M, Zwicky L, Hintermann B, et al. Risk factors for periprosthetic ankle joint infection: A case-control study. *J Bone Joint Surg Am* 2012; 94(20): 1871–6.
7. Bongartz T, Halligan CS, Osmon DR, Reinalda MS, Bamlet WR, Crowson CS, et al. Incidence and risk factors of prosthetic joint infection after total hip or knee replacement in patients with rheumatoid arthritis. *Arthritis Rheum* 2008; 59(12): 1713–20.
8. Tigges S, Stiles RG, Roberson JR. Complications of hip arthroplasty causing periprosthetic radiolucency on plain radiographs. *AJR Am J Roentgenol* 1994; 162: 1387–91.
9. Palestro CJ, Love C, Miller TT. Infection and musculoskeletal conditions: Imaging of musculoskeletal infections. *Best Pract Res Clin Rheumatol* 2006; 20: 1197–218.
10. Love C, Marwin SE, Palestro CJ. Nuclear medicine and the infected joint replacement. *Semin Nucl Med* 2009; 39(1): 66–78.
11. Palestro CJ, Love C. Radionuclide imaging of musculoskeletal infection: conventional agents. *Semin Musculoskelet Radiol* 2007; 11(4): 335–52.
12. Love C, Din AS, Tomas MB, Kalapparambath TP, Palestro CJ. Radionuclide bone imaging: an illustrative review. *Radiographics* 2003; 23(2): 341–58.
13. Ashbrooke AB, Calvert PT. Bone scan appearances after uncemented hip replacement. *J R Soc Med* 1990; 83(12): 768–9.
14. Rosenthal L, Lepanto L, Raymond F. Radiophosphate uptake in asymptomatic knee arthroplasty. *J Nucl Med* 1987; 28(10): 1546–9.
15. Hofmann AA, Wyatt RW, Daniels AU, Armstrong L, Alazraki N, Taylor A. Bone scans after total knee arthroplasty in asymptomatic patients: cemented versus cementless. *Clin Orthop Relat Res* 1990; 251: 183–8.
16. Love C, Tronco G, Yu A, Marwin S, Nichols K, Palestro C. Diagnosing lower extremity (LE) prosthetic joint infection: Bone, gallium & labeled leukocyte imaging. *J Nucl Med* 2008; 49(Suppl 1): 133P.
17. Smith SL, Wastie ML, Forster I. Radionuclide bone scintigraphy in the detection of significant complications after total knee joint replacement. *Clin Radiol* 2001; 56(3): 221–4.
18. Williamson BR, McLaughlin RE, Wang GW, Miller CW, Teates CD, Bray ST. Radionuclide bone imaging as a means of differentiating loosening and infection in patients with a painful total hip prosthesis. *Radiology* 1979; 133(3 Pt 1): 723–5.
19. Williams F, McCall IW, Park WM, O'Connor BT, Morris V. Gallium-67 scanning in the painful total hip replacement. *Clin Radiol* 1981; 32(4): 431–9.
20. Aliabadi P, Tumeb SS, Weissman BN, McNeil BJ. Cemented total hip prosthesis: radiographic and scintigraphic evaluation. *Radiology* 1989; 173(1): 203–6.
21. Palestro CJ, Swyer AJ, Kim CK, Goldsmith SJ. Infected knee prostheses: Diagnosis with In-111 leukocyte, Tc-99m sulfur colloid, and Tc-99m MDP imaging. *Radiology* 1991; 179(3): 645–8.

Received on March 03, 2016.  
Accepted on March 18, 2016.  
Online First June, 2016.